

Diaphragmatic Hernia Presenting as a Gastric Volvulus

PRATHVI SHETTY, LEO F. TAURO, RAJEEVKUMAR CHAUDHARY, UDAY KUMAR

ABSTRACT

Gastric volvulus is a rare clinical entity defined as an abnormal rotation of the stomach and it presents with the features of gastric outlet obstruction. The precipitating factors are usually idiopathic or due to abnormal laxity of the gastrosplenic, gastroduodenal, gastrophrenic and gastrohepatic ligaments or in cases of paraesophageal hernias. In adults, the most common causes of gastric volvulus are the diaphragmatic defects. We present a case of a 65 yrs old lady, who came with the symptoms of gastric

outlet obstruction, which on initial investigation pointed towards the diagnosis of a gastric volvulus. On laprotomy, the stomach was found to be incarcerated in a right-sided Morgagni hernia with surrounding adhesions. The hernia through the foramen of the Morgagni is uncommon in adults, accounting for only 3% of all the treated diaphragmatic hernias. The treatment for these hernias primarily is surgical repair or sometimes, repair by the use of prosthetic material. We report a rare case of a Morgagni hernia presenting as gastric volvulus.

Key Words: Gastric volvulus, Morgagni hernia, Diaphragmatic hernia

INTRODUCTION

A Morgagni hernia is a congenital herniation of the abdominal contents into the thoracic cavity through a retrosternal diaphragmatic defect. The reported incidence of congenital diaphragmatic hernias is estimated to be 1 in between 2000 to 5000 births. Morgagni hernias comprise 2% of all the diaphragmatic hernias. The foramen of the Morgagni hernia occurs in the anterior midline through the sternocostal hiatus of the diaphragm, with 90% of the cases occurring on the right side. Most of the Morgagni hernias are found and repaired in children, but 5% of them are found in adults [1]. They are usually asymptomatic and are often found incidentally on chest radiography. The symptoms of these hernias are attributable to the herniated viscera. In adults, diaphragmatic defects do present as a gastric volvulus [2]. We present a case of a 65 yrs old lady with Morgagni hernia, presenting as gastric volvulus.

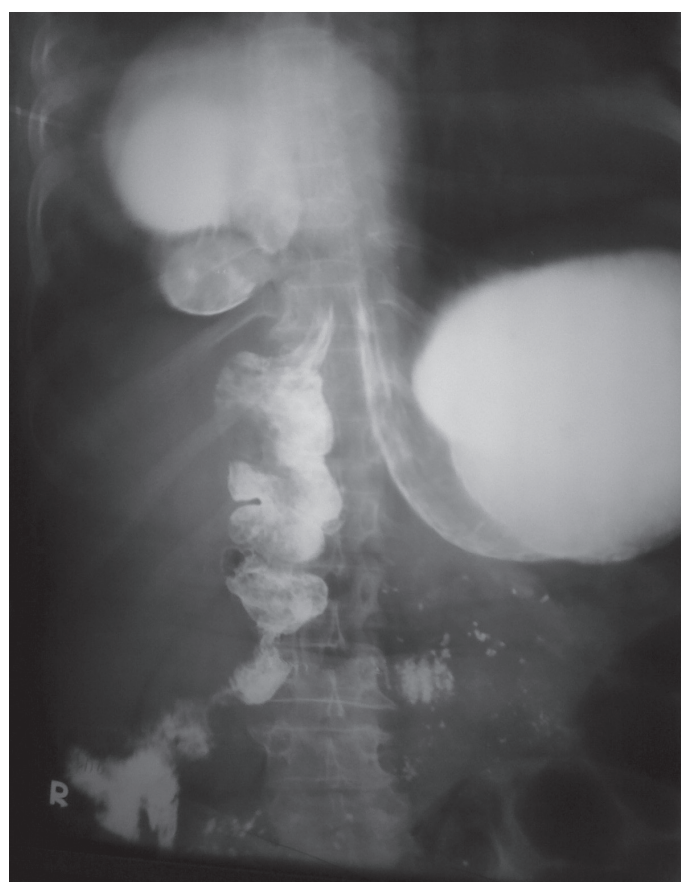CASE REPORT

A 65 yrs old lady presented to us with complaints of epigastric pain of 6 months duration, which was associated with retching and vomiting for one month. She used to vomit immediately after the intake of food. There was no history of fever, abdominal distension or bowel disturbances. On abdominal examination, epigastric tenderness was elicited. No palpable mass was found. The Digital rectal examination was normal.

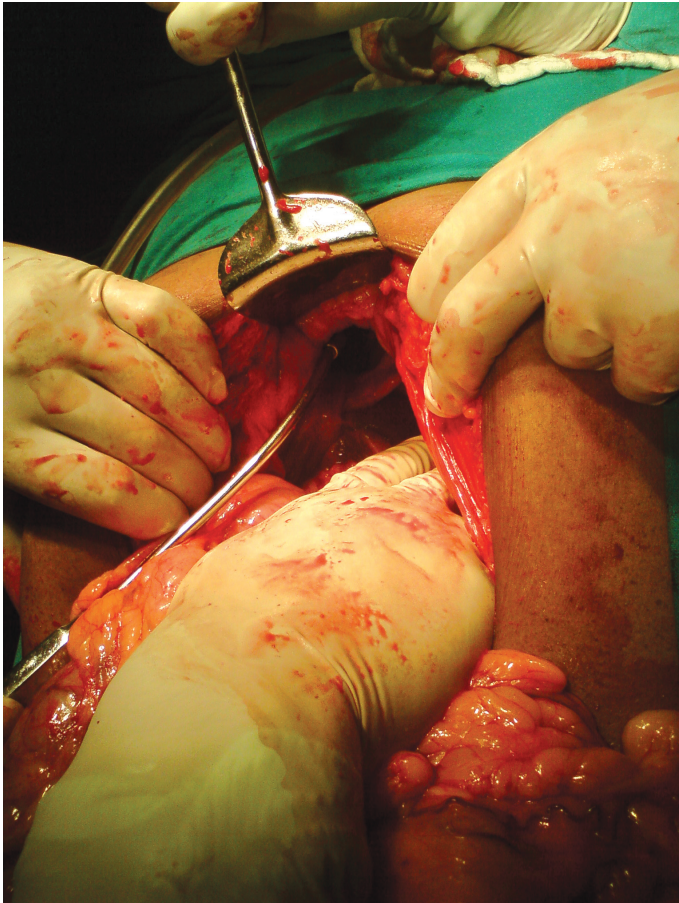
Her routine blood and urine examination results were within normal limits. Her abdominal ultrasound was normal. Upper gastrointestinal endoscopy could not be navigated past or pyloric antrum found and gastric volvulus was queried. A barium meal study showed an mesentrico axial type of gastric volvulus (Table/ Fig-1). On further detailed examination, the radiologist suggested the possibility of a Morgagni hernia with stomach herniation. A nasogastric tube placement was unsuccessful.

The abdomen was opened by making an upper midline incision. A right morgagni hernia with stomach and omental herniation,

which was associated with minimal adhesions was present. (Table/ Fig-2).The contents were reduced by using gentle traction and the defect was closed with suture material prolene 2.0 in two layers. The gastro-colic ligament was freed. A right ICD tube was inserted. The post operative period was uneventful. The patient was asymptomatic on 6 months of follow up.



[Table/Fig-1]: Barium meal study showing an mesentrico axial type of gastric volvulus due to stomach herniation in to right hemi thorax



[Table/Fig-2]: Stomach and omental herniation in to right hemi thorax

DISCUSSION

Diaphragmatic hernias can be divided into two broad categories: congenital diaphragmatic defects and acquired diaphragmatic defects. Congenital diaphragmatic hernias (CDH) occur when the muscular entities of the diaphragm fail to develop normally, resulting in the displacement of the abdominal components into the thorax and most patients present with it early in life rather than later. However, a subset of adults may present with a congenital hernia that was undetected during childhood [3].

The three basic types of congenital diaphragmatic hernias are posterolateral Bochdalek hernia anterior Morgagni hernia and the hiatus hernia. Left-sided Bochdalek hernia is seen in approximately 90% of the cases. Morgagni hernia is a less common form of congenital diaphragmatic hernia, occurring in only 5-10% of the cases. This hernia occurs in the anterior midline through the sternocostal hiatus of the diaphragm, with 90% of the cases occurring on the right side. Morgagni hernia is a rare type of congenital diaphragmatic hernia which may not be symptomatic until adulthood, when the patient presents with acute symptoms or incarceration [4].

Congenital hernias (of childhood or adult onset) present with obstructive symptoms like the protrusion of the colon, chest pain, tightness or fullness in the chest and sepsis following strangulation or perforation and many present with respiratory symptoms [5]. The diaphragmatic defects do present as gastric volvulus [2]. The classic triad which is associated with gastric volvulus of severe

epigastric pain, retching without vomiting, and inability to pass a nasogastric tube, was described by Borchart in 1904. This triad was present in our patient.

Plain pulmonary roentgenogram, radiological studies of the gastrointestinal system with contrast material, computerized tomography and magnetic resonance imaging studies are helpful in its diagnosis [6].

Surgical management is the right option and if it is in the neonatal period, a subcostal incision may be used. An attempt must be made to repair the hernia with a primary repair. However, a prosthetic material such as PTFE must sometimes be used. In the latent period, a thoracotomic or laparotomic approach can be used. Most surgeons make an approach with laparotomy so that the abdominal contents can be inspected adequately [7]. Minimally invasive approaches are currently being explored via video-assisted thoracoscopic or laparoscopic means [8]. Laparoscopy provides an excellent route for both the diagnosis and the repair of a Morgagni's hernia. The defect is repaired either by primary suture or by the use of a prosthetic mesh. In adults, a prosthetic non-absorbable mesh (PTFE, Polypropylene) repair is preferred to reconstruct or cover the defect. Extra corporeal or intra corporeal suture placement or staples are used to maintain the mesh in position. However, unless the mesh is covered with a layer of peritoneum, the intra-abdominal viscera may adhere to it, thus creating a setting in which small bowel obstruction is more likely at a future time. The use of staples alone to close the diaphragmatic defect has also been described but is only possible when a very small defect is present. Endoscopic surgery entails less postoperative pain and a shorter hospital stay.

CONCLUSION

This case report highlights the unusual presentation of obstructed viscera (Gastric volvulus) within a Morgagni's hernia in an elderly patient.

REFERENCES

- [1] Barut I, Tarhan OR, Cerci C, Akdeniz Y, Bulbul M. Intestinal obstruction caused by a strangulated Morgagni hernia in an adult patient. *J Thoracic Imaging*. 2005; 20:220-2.
- [2] Iso Y, Sawada T, Rokkaku K, Furihata T, Shimoda M, Kita J, et al. A case of symptomatic Morgagni's hernia and a review of Morgagni's hernia in Japan (263 reported cases) *Hernia*. 2006;10:521-4
- [3] Wiseman NE, MacPherson RI. "Acquired" congenital diaphragmatic hernia. *J Pediatr Surg*. 1977;12:657-65.
- [4] Rogers FB, Rebeck J A Case report: Morgagni hernia. *Hernia*. 2006 ; 10(1):90-2..
- [5] Harford WV, McArthur KE. Diverticula, hernias, volvulus, and rupture. In: Sleisenger MH, Fordtran JS. *Gastrointestinal Disease: Pathophysiology, Diagnosis, Management*. 5. Philadelphia, PA: Saunders; 1993:481-483.
- [6] Colakoglu O, Hacıyanlı M, Soyutürk M, Colakoglu G, Simek I. Morgagni hernia in an adult: atypical presentation and diagnostic difficulties *Türk J Gastroenterol*. 2005;16:114-6.
- [7] Yılmaz M, Isik B, Coban S, Sogutlu G, Ara C, Kirimlioglu V, Yılmaz S, Kayaalp C. A transabdominal approach in the surgical management of Morgagni hernia. *Surg Today*. 2007;37:9-13.
- [8] Durak E, Gur S, Cokmez A, Atahan K, Zahtz E, Tarcan E. Laparoscopic repair of Morgagni hernia. *Hernia*. 2007;11:265-70.

AUTHOR(S):

1. Dr. Prathvi Shetty
2. Dr. Leo F. Tauro
3. Dr. Rajeevkumar Chaudhary
4. Dr. Uday Kumar

NAME OF DEPARTMENT(S)/INSTITUTION(S) TO WHICH THE WORK IS ATTRIBUTED:

Department of surgery, Father Muller Medical Collage and Hospital. Kankanady, Mangalore - 575002, Karnataka, India.

NAME, ADDRESS, TELEPHONE, E-MAIL ID OF THE CORRESPONDING AUTHOR:

Dr. Shetty Prathvi, Department of Surgery
FMMCH, Kankanady, Mangalore-575002
Karnataka, India.
Mobile: +91-9886839423
E-mail: prathviz@gmail.com

DECLARATION ON COMPETING INTERESTS:

No competing Interests.

Date of Submission: **May 17, 2011**

Date of Peer Review: **May 25, 2011**

Date of Acceptance: **May 27, 2011**

Date of Publishing: **Aug 08, 2011**